



Case Report

Severe anemia caused by secondary myelofibrosis in a patient with angioimmunoblastic peripheral T-cell lymphoma

Jaemin Jo¹, Jeong Ho Kang² ✉

¹Department of Internal medicine, Jeju National University School of Medicine, Jeju, Republic of Korea

²Department of Emergency Medicine, Jeju National University School of Medicine, Jeju, Republic of Korea

Abstract Bone marrow failure, such as aplastic or myelophthitic anemia, can occur due to an underlying lymphoid malignancy and cause life-threatening events. A 58-year-old man diagnosed with angioimmunoblastic T-cell lymphoma had recently visited the emergency department because of an altered level of consciousness caused by acute severe anemia. The laboratory findings were strongly suggestive of bone marrow failure syndrome. Bone marrow examination was immediately performed and, subsequently, dexamethasone was initiated to control the underlying lymphoma. Intravenous immunoglobulin was also administered in combination due to combined immune hemolytic anemia and thrombocytopenia. Bone marrow examination revealed a packed marrow with marked fibrosis and lymphoma involvement. A diagnosis of secondary myelofibrosis related to the underlying lymphoma was made, and sequential combination chemotherapy was introduced despite the presence of severe anemia and thrombocytopenia. After combination chemotherapy, his hematologic profile and underlying lymphoma improved. Better understanding of various hematologic manifestations and knowledge of the rare condition of lymphoma are essential for appropriate diagnostic approaches and treatment.

Key words: Bone marrow failure, Angioimmunoblastic T-cell lymphoma, Anemia, Diagnosis

INTRODUCTION

Oncology patients with anemia are frequently encountered in the emergency department (ED); hence, differential diagnosis of the cause of anemia and appropriate treatments are important for patients' prognosis. Bone marrow failure due to secondary myelofibrosis by oncologic etiologies is a rare condition in the ED, but it can cause life-threatening conditions.^{1,2)} We herein describe the diagnostic modality and treatment approach for severe anemia due to lymphoma-related secondary myelofibrosis.

Received: July 15, 2020; Revised: July 28, 2020; Accepted: August 6, 2020

✉ Correspondence to : Jeong Ho Kang

Department of Emergency Medicine, Jeju National University School of Medicine 15, Aran 13-gil, Jeju-si, Jeju-do 63241, Republic of Korea
Tel: 82-64-717-1924, FAX: 82-64-717-1168
E-mail: sivakjh1234@gmail.com

CASE REPORT

A 58-year-old man was admitted to the ED due to drowsy mental status. The patient had complaints of poor oral intake and general weakness since a week ago and variation in the drowsy level of consciousness two days ago. Two weeks before his admission, he presented to the ED with abdominal discomfort and weight loss, and abdomen and chest computed tomography (CT) revealed generalized lymph node enlargement. He was admitted for further evaluation and a final diagnosis of angioimmunoblastic T-cell lymphoma (AITL) was made after neck lymph node excisional biopsy. However, the patient was lost to follow-up because he wanted to seek for a second opinion from a tertiary university hospital in another province.

On arrival to the ED, the patient had the following vital

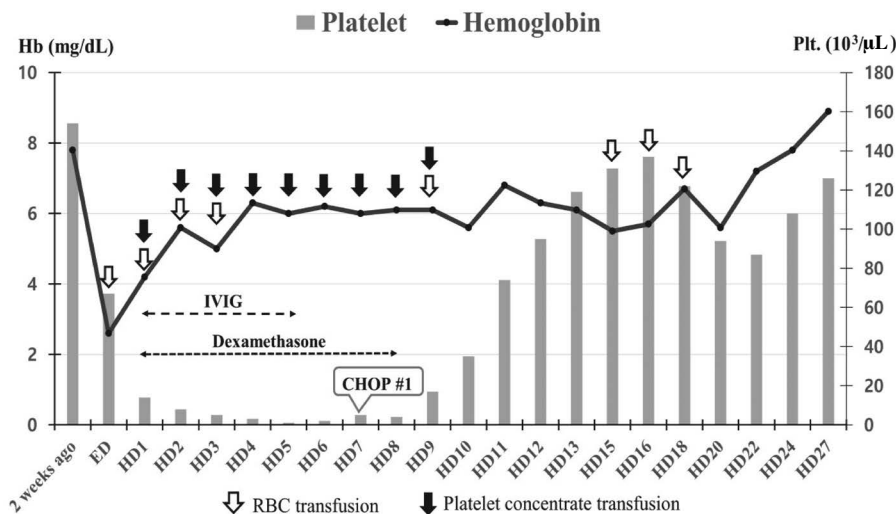


Figure 1. Changes in hemoglobin and platelet levels according to treatments during hospitalization (Hb, hemoglobin; Plt, platelet; IVIG, intravenous immunoglobulin; CHOP, combination therapy of cyclophosphamide, doxorubicin, vincristine, and prednisone).

signs: blood pressure, 115/60 mmHg; body temperature, 38.7°C; pulse rate, 92 beats/min; respiratory rate, 20 breaths/min; and Glasgow coma scale, 9 points. Physical examination revealed a severely dehydrated state and anemic conjunctiva. Brain CT was performed to differentially diagnose the cause of the altered consciousness, but no specific structural lesions were observed. Initial laboratory tests showed the following results: leukocyte count, 3,300/μL; hemoglobin (Hb), 2.6 g/dL; platelet count, 67,000/μL; mean corpuscular volume, 87.6 fL; mean corpuscular hemoglobin, 29.2 pg; red cell distribution width, 13.1%; lactate dehydrogenase, 701 IU/L; total bilirubin, 1.3 mg/dL; blood urea nitrogen, 24.6 mg/dL; creatine, 0.9 mg/dL. The results of other laboratory tests were within normal limits.

Compared with the Hb level of 9.4 g/dL two weeks ago, acute progression of the severe normocytic anemia was noted. To differentially diagnose the cause of anemia, we performed additional anemia workup and evaluated whether the anemia was due to acute blood loss such as in gastrointestinal bleeding. The anemia workup results showed a haptoglobin level of below 8 mg/dL and reticulocyte value of 0.06%. Indirect and direct Coombs tests were both positive, and the cold agglutinin titer was 1 : 32. Additionally, peripheral blood smear revealed pancytopenia with rouleaux formation without evidence of leukoerythroblastic reaction. Fe, folate, and vitamin B12 levels were within normal limits, and there was no evidence of acute blood loss. As a result of the ED evaluation, bone marrow failure such as aplastic anemia related to underlying lymphoid malignancy was initially suspected based on the extremely

low level of reticulocytes and combined autoimmune hemolytic anemia (AIHA) and immune thrombocytopenia (ITP) was also considered due to the positive Coombs tests results and low haptoglobin.

After bone marrow examination to evaluate etiology, we administered high-dose steroids and intravenous immunoglobulin transfusion to the patient, which was marginally effective (Fig. 1). After the confirming minimal lymphoma involvement and marked secondary myelofibrosis from a bone marrow examination after a few days of hospitalization, the combination CHOP (cyclophosphamide, doxorubicin, vincristine, and prednisone) regimen was very cautiously introduced, and his hematologic profile was dramatically improved. After completing the CHOP chemotherapy, the patient recovered with nearly normalized hematologic profiles and was discharged without serious complications.

DISCUSSION

Anemia is defined as a decrease in blood Hb concentration or RBC mass, thereby decreasing the oxygen-carrying capacity of the blood. The World Health Organization defines anemia as a Hb level of less than 13 g/dL in adult males and 12 g/dL in adult females, which includes the definition of anemia as the lowest 2.5% of Hb levels in a healthy population.²⁾ Anemia is a common condition that is diagnosed based on laboratory test results in patients visiting the ED. In most cases, anemia is a sign of an underlying disease and

is not the final diagnosis. Therefore, the goal of diagnostic evaluation in the ED is to determine the underlying cause of the anemia. Moreover, emergency physicians should carefully evaluate life-threatening conditions that require timely treatment.^{2,4)} In case of anemia with other hematologic abnormalities such as other cytopenia or abnormal cells on peripheral blood smear, an unusual cause of the disease should be suspected. Pancytopenia or bicytopenia is caused by various types of etiologies including congenital bone marrow failure syndrome, idiopathic aplastic anemia, nutritional deficiency, sequestration, autoimmune disease, and bone marrow infiltrative disease. Therefore, the differential diagnosis should include these disease entities, and disease-specific diagnostic approaches are required.⁵⁾

In this case, AITL was diagnosed by histological evaluation and immunophenotyping of the lymph node upon biopsy. AITL is characterized by monoclonal proliferation of the follicular T helper cell expressing CD3 and CD4. AITL represents only 1%~2% of all non-Hodgkin lymphoma cases. AITL occurs mainly in elderly people in their 60s and 70s, and the most common presenting symptom is generalized lymphadenopathy, which is often accompanied by B symptoms (fever, weight loss, and night sweats).⁶⁾ Currently, anthracycline-based chemotherapy is considered the first-line therapy for AITL. There was no difference in overall survival rate when comparing different anthracycline-based regimens: CHOP, ACVBP (dose-intense doxorubicin, cyclophosphamide, vindesine, bleomycin, and prednisone), or mBACOD (methotrexate, bleomycin, doxorubicin, cyclophosphamide, vincristine, and dexamethasone). In AITL patients treated with first-line therapy, complete remission rates were reported as 61%, with five-year overall survival and recurrence-free survival rates reported as 32~33% and 18%, respectively. High-dose chemotherapy followed by autologous stem cell transplantation can improve the likelihood of complete remission.^{6,7)}

AITL can be disguised as an immune activator with a high erythrocyte sedimentation rate and lead to positive autoimmune tests such as rheumatoid factor, antinuclear factor, and anti-smooth muscle factor. Thus, AITL can cause various hematologic abnormalities associated with autoimmune reactions such as warm-type AIHA, ITP, and lymphocytopenia.^{8,9)} In this case, the main cause of hematologic abnormalities including severe anemia and thrombocytopenia was bone marrow failure caused by lymphoma-related secondary myelofibrosis, with AIHA and ITP contributing in part. This etiology of cytopenia is rarely manifested by lymphoma patients and difficult to suspect initially.⁵⁾ Previous studies have reported that anti-lymphoma

treatments effectively improve cytopenia caused by bone marrow fibrosis.¹⁰⁻¹²⁾ Therefore, we gradually introduced combination chemotherapy with a reduced dose and observed a remarkably improved hematologic profile. Subsequent bone marrow biopsy also revealed normal bone marrow findings after several cycles of CHOP chemotherapy.

CONCLUSIONS

In this case report, we presented a diagnostic approach and treatment for severe anemia caused by rare etiologies in patients with lymphoma. In many patients with cancer, anemia is frequently confirmed by routine laboratory tests. However, rare but fatal hematologic complications caused by lymphoma are difficult to diagnose without physician's suspected diagnosis. Better understanding of the rare clinical manifestations of lymphoma is essential for appropriate diagnostic approaches and effective treatment for patients with life-threatening hematologic complications.

ETHICAL APPROVAL

This study was approved by the institutional review board (IRB) of Jeju National University Hospital (IRB No. 2020-05-009). The requirement for informed consent was waived by the IRB.

Conflict of Interest: No potential conflict of interest relevant to this article was reported.

Funding/Support: None declared.

REFERENCES

1. Swenson KK, Rose MA, Ritz L, Murray CL, Adlis SA. Recognition and evaluation of oncology-related symptoms in the emergency department. *Ann Emerg Med* 1995;26:12-7.
2. Vieth JT, Lane DR. Anemia. *Emerg Med Clin North Am* 2014;32: 613-28.
3. Blackman SC, del Rey JAG. Hematologic emergencies: acute anemia. *Clin Pediatr Emerg Med* 2005;6:124-37.
4. Long B, Koyfman A. Emergency medicine evaluation and management of anemia. *Emerg Med Clin North Am* 2018;36:609-30.
5. Weinzierl EP, Arber DA. The differential diagnosis and bone marrow evaluation of new-onset pancytopenia. *Am J Clin Pathol* 2013;139: 9-29.
6. Lunning MA, Vose JM. Angioimmunoblastic T-cell lymphoma: the

- many-faced lymphoma. *Blood Adv* 2017;129:1095-102.
7. Mosalpuria K, Bociek RG, Vose JM. Angioimmunoblastic T-cell lymphoma management. *Semin Hematol* 2014;51:52-8.
 8. De Leval L, Gisselbrecht C, Gaulard P. Advances in the understanding and management of angioimmunoblastic T-cell lymphoma. *Br J Haematol* 2010;148:673-89.
 9. Dogan A, Attygalle AD, Kyriakou C. Angioimmunoblastic T-cell lymphoma. *Br J Haematol* 2003;121:681-91.
 10. Meadows LM, Rosse WR, Moore JO, Crawford J, Laszlo J, Kaufman RE. Hodgkin's disease presenting as myelofibrosis. *Cancer* 1989;64:1720-6.
 11. Takai K, Sanada M. Peripheral T-cell lymphoma initially presenting as secondary myelofibrosis. *Rinsho Ketsueki* 1989;30:2199-204.
 12. Uehara E, Tasaka T, Matsuhashi Y, Fujita M, Tamura T, Shimoura Y, et al. Peripheral T-cell lymphoma presenting with rapidly progressing myelofibrosis. *Leuk Lymphoma* 2003;44:361-3.