



Case Report

# Safety of radiotherapy in patients with Behcet's disease: a case report and review of the literature

Dahui Ko<sup>1</sup>, Young Suk Kim<sup>2</sup>, Yunseon Choi<sup>3</sup>✉

<sup>1</sup>Jeju National University College of Medicine, Jeju, Republic of Korea

<sup>2</sup>Department of Radiation Oncology, Jeju National University Hospital, Jeju National University College of Medicine, Jeju, Republic of Korea

<sup>3</sup>Department of Radiation Oncology, Inje University Busan Paik Hospital, Inje University College of Medicine, Busan, Republic of Korea

**Abstract** Exaggerated acute and late toxicities following radiotherapy have been reported in patients with pre-existing connective tissue diseases, such as systemic lupus and scleroderma. Behcet's disease (BD) is a relapsing multisystem connective tissue disease characterized by vasculitis in the mucocutaneous, ocular, gastrointestinal, respiratory, neurologic, urogenital, articular, and cardiovascular systems. Data concerning the relationship between radiotherapy toxicity and BD are limited in the literature. Here, we report a case of lung cancer treated with radiotherapy (60 Gy) in a patient with BD. No severe radiation-induced toxicity was observed. Radiation-induced toxicity in patients with BD has also been discussed.

**Key words:** Behcet's disease, Neoplasms, Radiotherapy, Toxicity

## INTRODUCTION

Behcet's disease (BD) is a relapsing inflammatory disorder of unknown etiology that manifests as recurrent oral aphthous ulcers, genital ulcers, uveitis, and skin lesions.<sup>1)</sup> Most reports on severe toxicities, such as skin atrophy, skin necrosis, and fibrosis, after radiotherapy in patients with connective tissue diseases, involve patients with systemic lupus, rheumatoid arthritis, or scleroderma.<sup>2)</sup> However, data

concerning the relationship between radiotherapy toxicity and BD are limited in the literature. Herein, we describe the case of a patient with concomitant lung cancer and BD. Radiation-induced toxicity in patients with BD has also been discussed.

## CASE REPORT

In February 2018, a 70-year-old man presented with a 3.5-cm nodule in the left upper lobe of the lung on chest radiography. The patient was a 50 pack-year current smoker with a medical history of hypertension, atrial fibrillation, intracerebral hemorrhage, and left middle cerebral artery infarction. The patient quit smoking in May 2018. Twenty-three years prior to presenting with the lung nodule, the patient

Received: July 23, 2021; Revised: August 20, 2021; Accepted: August 23, 2021

✉ Correspondence to : Yunseon Choi  
Department of Radiation Oncology, Inje University Busan Paik Hospital,  
Inje University College of Medicine, 75 Bokji-ro, Busanjin-gu, Busan 47392,  
Republic of Korea  
Tel: 82-51-890-8606, Fax: 82-51-891-1754  
E-mail: rtyoon@gmail.com

underwent clipping surgery for a cerebral artery aneurysm. At that time, he was diagnosed with BD, with symptoms of recurrent oral and genital ulcers, and knee arthritis and was prescribed oral colchicine. In addition to the chest X-ray, a computed tomographic scan of the chest revealed a 3.8-cm malignant-looking mass in the left perihilar area and an enlarged lymph node in the left hilum. Surgery was recommended, but the patient refused.

In March 2019, the patient presented with dyspnea on exertion, cough, a 10-kg weight loss over the previous year, general weakness, and loss of appetite. The Eastern Coop-

erative Oncology Group performance status score was 2. Bronchoscopy revealed total obstruction of the left upper lobe main bronchus with a mass. Biopsy of the primary tumor revealed a poorly differentiated squamous cell carcinoma. Computed tomography of the chest revealed obstructive atelectasis and necrotizing pneumonia in the left upper lobe, enlarged lymph nodes in the left paratracheal area, hilum, and subcarina, and left malignant pleural effusion. Irregular atherosclerotic wall thickening in the aortic arch and abdominal aorta, penetrating ulcers at the aortic arch, and aneurysmal dilatation in the ascending aorta (4.3 cm) and descending thoracic aorta (3.5 cm) were also noted. The clinical stage was T4 N2 M1a. The patient had been treated with oral colchicine for BD at the time of radiotherapy. Oral and genital ulcers had been stable for 9 months before radiotherapy. Palliative radiotherapy for left upper lobe obstruction was recommended. The primary left hilar lesion received 60 Gy in 30 fractions (Figs. 1, 2). During radiotherapy, the patient experienced grade 1 esophagitis and a grade 1 skin reaction (redness on the anterior chest wall and back) (Table 1). One month after completion of radiotherapy, the primary left hilar lesion had decreased and the obstruction of the left upper lobe main bronchus had improved; however, lumbar spine (L1) metastasis and single 7-mm brain metastasis

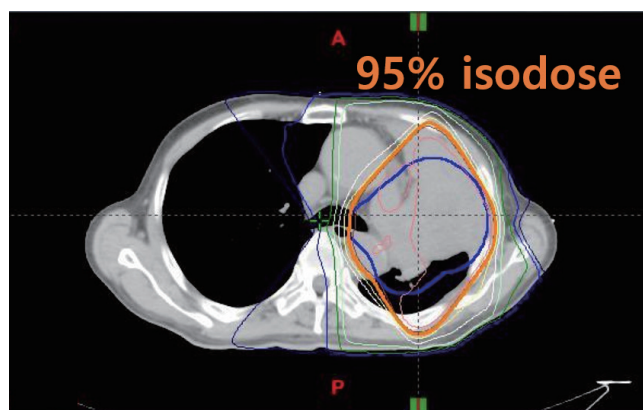


Figure 1. Isodose curves on an axial image.

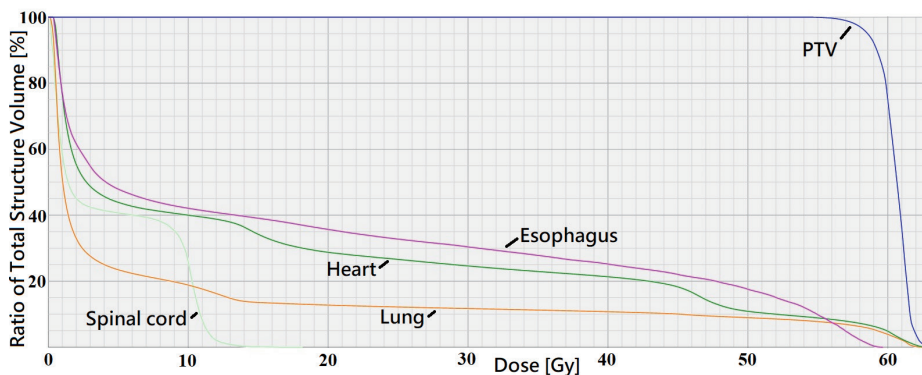


Figure 2. Dose volume histogram curves.

Table 1. Toxicity related to radiotherapy in our case

Age	Sex	Malignancy	Treatment	RT site	RT dose	Acute toxicity	Late toxicity	Comments
71	M	Lung	RT	Mediastinum,	60 Gy/30 fr	Esophagitis Gr 1,	No	4 months f/u
			No chemotherapy	Lung		Skin redness		3DCRT
				Brain	35 Gy/10 fr	No	NA	Whole brain RT with SIB
				T12- L2 spine	30 Gy/10 fr	No	NA	3DCRT

M: male, RT: radiotherapy, NA: not applicable, f/u: follow-up, Gr: grade, 3DCRT: 3-D conformal radiotherapy, SIB: simultaneous integrated boost.

**Table 2.** Toxicity related to radiotherapy in cancer patients with Behcet's disease

Study	Age	Sex	Malignancy	Treatment	RT site	RT dose	Acute toxicity	Late toxicity (months)	Comments
Kaneko et al. (1974) <sup>8</sup>	32	M	Nasal cavity lymphoma	RT, prednisolone, CT	Nasal cavity	40 Gy	Tolerable	Tolerable	5 months f/u
Harada et al. (1992) <sup>9</sup>	43	F	Intracranial lymphoma	RT, prednisolone	Brain	NA	Tolerable	Tolerable	No problems in daily life
Muramatsu et al. (1998) <sup>10</sup>	47	M	Thigh, sarcoma	Surgery, RT	Thigh	66 Gy	NA	NA	36 months f/u
Strohal et al. (1998) <sup>11</sup>	21	M	Castleman's disease	CT, RT, Interferon- $\alpha$	Heart, neck, mediastinum	40 Gy	Tolerable	Tolerable	44 months f/u
Cengiz et al. (2001) <sup>6</sup>	47	M	Hodgkin's disease	CT, RT	Mantle field	40 Gy	No increase in severity or incidence of acute radiation morbidity	Brachial plexopathy (6)	Pain in the left upper arm
	54	F	Uterine cervix	Surgery, RT	Pelvis	50 Gy		Left ureteral stricture (4)	Percutaneous nephrostomy
	44	M	Bladder	CT, RT	Pelvis	30 Gy		No	
	25	M	Thigh, sarcoma	Surgery, CT, RT	Thigh	70 Gy		Skin necrosis (6)	Surgical intervention
	46	F	Uterine cervix	Surgery, CCRT	Pelvis	50.4 Gy		No	
43	F	Breast	Mastectomy, CT, RT	Chest wall	50 Gy	No			
Satolli et al. (2005) <sup>12</sup>	67	M	Merkel cell carcinoma	RT, CT	Skin, forearm	NA	NA	NA	Died 7 months after RT
Ono et al. (2005) <sup>13</sup>	75	F	Intracranial lymphoma	Surgery, adjuvant RT	Brain	50 Gy	Tolerable	Tolerable	7 months f/u
Kaklamani et al. (2005) <sup>14</sup>	44	M	Lung	CT, RT	Brain	NA	NA	NA	
Lee et al. (2006) <sup>15</sup>	40	M	Colon	Surgery, CT, adjuvant RT	Abdomen	NA	No	No	20 months f/u
Souabni et al. (2008) <sup>16</sup>	46	M	Tonsillar lymphoma	CT, RT	Tonsil, neck	45 Gy	Tolerable	Tolerable	4 years f/u
Meyer et al. (2008) <sup>2</sup>	53	M	Lung	CCRT (cisplatin, etoposide)	Mediastinum	64 Gy	Esophagitis Gr 2, bronchoesophageal fistula		5 weeks after completing RT
Chargari et al. (2009) <sup>5</sup>	61	F	Breast	Lumpectomy, RT	Breast	44 Gy/22 fr	Epithelitis Gr 3		Interruption of RT
Ahn et al. (2010) <sup>17</sup>	48	F	Rectum	Surgery, CCRT	Pelvis	NA	NA	NA	
	34	M	Rectum	Surgery, CCRT	Pelvis	NA	NA	NA	
Na et al. (2013) <sup>4</sup>	49	F	Breast	Mastectomy, CT, RT	Chest wall	NA	No	No	
	52	M	Rectum	Surgery, CCRT	Pelvis	NA	No	No	

Table 2. Continued

Study	Age	Sex	Malignancy	Treatment	RT site	RT dose	Acute toxicity	Late toxicity (months)	Comments
	53	F	Colon	Surgery, CCRT	Pelvis	NA	No	No	
Karatas et al. (2018) <sup>3</sup>	38-56	F	Breast	Mastectomy/lumpectomy, CT (80%), HT (70%), RT	Breast/chest wall	NA	No	No	No RT complications in 10 patients

RT: radiotherapy, CT: chemotherapy, NA: not applicable, CCRT: concurrent chemoradiotherapy, HT: hormone therapy.

in the right medial temporal lobe developed. Hippocampus-sparing whole brain radiotherapy with simultaneous integrated boost was applied at 35 Gy in 10 fractions for the right medial temporal lobe gross tumor and at 25 Gy in 10 fractions for the whole brain. The lumbar spine received 30 Gy in 10 fractions. No radiation-induced toxicities were observed. The patient did not undergo chemotherapy. In August 2019, 6 weeks after the completion of spine and brain radiotherapy, the patient died from obstructive pneumonia in the left upper lobe. This study was approved by the Institutional Review Board of the Jeju National University Hospital (IRB No. 2021-03-07).

## DISCUSSION

In our case, there was no severe acute or late radiation-induced toxicity in the lung or mediastinum. Karatas et al.<sup>3</sup> reported no radiation-induced toxicity in 10 patients with breast cancer. Na et al.<sup>4</sup> reported that radiotherapy was performed in three patients (breast, rectum, and colon) without complications (Table 2). On the other hand, several severe acute and late radiation-induced toxicity events have been reported in patients with BD.<sup>2,5,6</sup> Chargari et al.<sup>5</sup> observed grade 3 epithelitis during adjuvant radiotherapy (44 Gy in 22 fractions) in a patient with breast cancer, which resulted in an interruption of radiotherapy. Meyer et al.<sup>2</sup> reported a bronchoesophageal fistula 5 weeks after the completion of definitive radiotherapy (64 Gy) and chemotherapy (cisplatin and etoposide) in a patient with lung cancer. They recommended considering screening for esophageal ulcers before initiating treatment for thoracic tumors in patients with BD.<sup>2</sup> Concurrent use of chemotherapy and high radiation dose may have contributed to the severe toxicity. Cengiz

et al.<sup>6</sup> reported three severe late toxicity reactions after radiotherapy in patients with BD (Table 2). A patient with Hodgkin's disease developed brachial plexopathy (pain in the left upper arm) 6 months after the completion of radiotherapy (40 Gy) to the mantle field. Another patient developed left ureteral stricture 4 months after the completion of postoperative radiotherapy (50 Gy) for cervical cancer. A third patient with a thigh mesenchymal tumor developed skin necrosis 6 months after the completion of postoperative radiotherapy (70 Gy).

The pathogenesis of BD remains unclear. A combination of infectious agents, immune disorders, environmental factors, and genetic factors may be related to BD.<sup>7</sup> Benderli Cihan et al.<sup>7</sup> recommended that during periods of exacerbation, BD patients receiving radiation treatment should be closely monitored for acute and chronic toxicity. In our case, recurrent oral and genital ulcers had been quiescent for 9 months before radiotherapy.

## CONCLUSIONS

A limitation of our report is that the follow-up period after the completion of radiotherapy was only 4 months, which is too short to evaluate the effects of late toxicity. The total radiation dose and treatment volume can affect the level of toxicity. In our case, the total radiation dose was 60 Gy, and most of the esophagus and mediastinum were excluded from the scope of the radiation treatment. These factors may have contributed to mild toxicity.

The relationship between BD and radiation-induced toxicity remains controversial. Several severe acute and late radiation-induced toxicity events have been reported. We need to be cautious when applying radiotherapy in patients with

BD. Further studies regarding acute and late toxicity may be required to clarify the safety of radiotherapy in patients with BD.

## REFERENCES

1. Sakane T, Takeno M, Suzuki N, Inaba G. Behçet's disease. *N Engl J Med* 1999;341:1284-91.
2. Meyer J, Wahidi M, Shofer S, Evans J, Crawford J, Kelsey CR. Formation of a bronchoesophageal fistula following concurrent radiation and chemotherapy for lung cancer in the setting of Behçet's disease. *J Thorac Oncol* 2008;3:1361-2.
3. Karatas F, Sahin S, Aytekin A, Erdem GU, Ates O, Ozisik Y, et al. Behçet's disease and breast cancer: a case series study. *J Cancer Res Ther* 2018;14:1184-90.
4. Na SY, Shin J, Lee ES. Morbidity of solid cancer in Behçet's disease: analysis of 11 cases in a series of 506 patients. *Yonsei Med J* 2013;54:895-901.
5. Chargari C, Kirova YM, Fourquet A, Campana F. Severe acute radiation-related skin toxicity in a breast cancer patient with Behçet's disease. *Radiother Oncol* 2009;91:139.
6. Cengiz M, Altundag MK, Zorlu AF, Güllü IH, Ozyar E, Atahan IL. Malignancy in Behçet's disease: a report of 13 cases and a review of the literature. *Clin Rheumatol* 2001;20:239-44.
7. Benderli Cihan Y, Sarigoz T. Which situations require attention during radiotherapy in patients with Behçet's disease-associated malignancy? *J BUON* 2016;21:522.
8. Kaneko H, Hojo Y, Nakajima H, Okamura A, Fukase M. Behçet syndrome associated with nasal malignant lymphoma--report of an autopsy case. *Acta Pathol Jpn* 1974;24:141-50.
9. Harada K, Ohtsuru K, Nakayama K, Takagi S, Sugita Y, Torigoe R. Intracranial primary malignant lymphoma following Behçet's disease--case report. *No To Shinkei* 1992;44:1029-33.
10. Muramatsu M, Kotake S, Yoshikawa K, Sasamoto Y, Matsuda H, Yamawaki S. The development of malignant rhabdoid tumor in a patient with Behçet's disease treated with ciclosporin. *Graefes Arch Clin Exp Ophthalmol* 1998;236:798-9.
11. Strohal R, Tschachler E, Breyer S, Uthman A, Simonitsch I, Trating S, et al. Reactivation of Behçet's disease in the course of multicentric HHV8-positive Castleman's disease: long-term complete remission by a combined chemo/radiation and interferon-alpha therapy regimen. *Br J Haematol* 1998;103:788-90.
12. Satolli F, Venturi C, Vescovi V, Morrone P, De Panfilis G. Merkelcell carcinoma in Behçet's disease. *Acta Derm Venereol* 2005;85:79.
13. Ono Y, Yamada M, Kawamura T, Ito J, Kanayama S, Katayama Y, et al. Central nervous system malignant lymphoma associated with Behçet's disease. Case report. *Neurol Med Chir (Tokyo)* 2005;45:586-90.
14. Kaklamani VG, Tzonou A, Kaklamanis PG. Behçet's disease associated with malignancies. Report of two cases and review of the literature. *Clin Exp Rheumatol* 2005;23(4 Suppl 38):S35-41.
15. Lee JE, Sohn JW, Lee KH, Park YS, Kim KH, Choi JW, et al. Colon cancer in Behçet's disease. *Yeungnam Univ J Med* 2006;23:124-30.
16. Souabni L, Elleuch M, Amira C, Sellami S. Malignant lymphoma of the tonsil in a patient with Behçet's disease. *Joint Bone Spine* 2008;75:616-8.
17. Ahn JK, Oh JM, Lee J, Koh EM, Cha HS. Behçet's disease associated with malignancy in Korea: a single center experience. *Rheumatol Int* 2010;30:831-5.